

Wound Healing

A New Perspective with Particular Reference to Ascorbic Acid Deficiency *

J. ENGLEBERT DUNPHY, M.D., F.A.C.S.,** K. N. UDUPA, F.R.C.S. (C),***
LEON C. EDWARDS, M.D.****

Boston, Massachusetts

*From the Department of Surgery, Harvard Medical School; The Fifth Surgical Service and
Sears Surgical Laboratory, Boston City Hospital and The Surgical Service,
Peter Bent Brigham Hospital*

HOW WOUNDS HEAL has been a concern of surgeons since the dawn of medicine. In the beginning it was thought that "humors" within the body affected repair as evidenced by the statement attributed to Paracelsus, "There is an inborn balsam which heals wounds." This notion of a humoral factor in healing dominated surgical writing until Virchow's studies in cellular pathology provided a scientific background for the investigation of injury and repair. From that time until the present surgeons have looked upon wound healing largely as a cellular phenomenon, first in terms of histology and later, following the classic

contribution of Harvey and Howes,^{1,2} in terms of tensile strength as a quantitative measure of cellular proliferation. Extensive investigations¹ in the last decade into the nature and function of connective tissue now make it apparent that in a broad sense there are "humoral factors" in wound healing which merit study and analysis quite as much as the more established cellular changes. This paper reviews our efforts to elucidate the nature of repair in normal and protein depleted animals in terms of "humoral" as well as "cellular" pathology and it records our observations along the same lines on scorbutic animals. It also describes a sponge biopsy technic designed to apply these studies to primarily closed wounds both in experimental animals and in man.

* Presented before the American Surgical Association, White Sulphur Springs, West Virginia, April 11, 1956.

Supported in part by An American Cancer Society Institutional Grant to Harvard University; in part by the William F. Milton Fund of Harvard University; in part by a research grant (RG-3949-R2) from the National Institutes of Health, Public Health Service; and in part by the Office of the Surgeon General, Department of the Army, through a contract with Harvard University.

** Professor of Surgery, Harvard Medical School; Director of The Fifth Surgical Service and Sears Surgical Laboratory, Boston City Hospital.

*** Civil Surgeon, Himachal Pradesh Hospital, Snowdon, Simla, India; formerly Research Fellow in Surgery, Harvard Medical School; Assistant in Surgery, Peter Bent Brigham Hospital.

**** Research Fellow in Surgery, Harvard Medical School and Sears Surgical Laboratory, Boston City Hospital.

CONCEPT AND METHOD OF STUDY

It is well established that a viscous, amorphous, gel-like material occupies the spaces between bundles of connective tissue fibers.^{2,4} This material, the connective tissue ground substance, is present very early in embryonic development. Its properties vary with age, under various conditions and in different body tissues. In addition to water, electrolytes, enzymes and products of metabolism, ground substance contains soluble proteins, mucoproteins and polysaccharide protein complexes. These

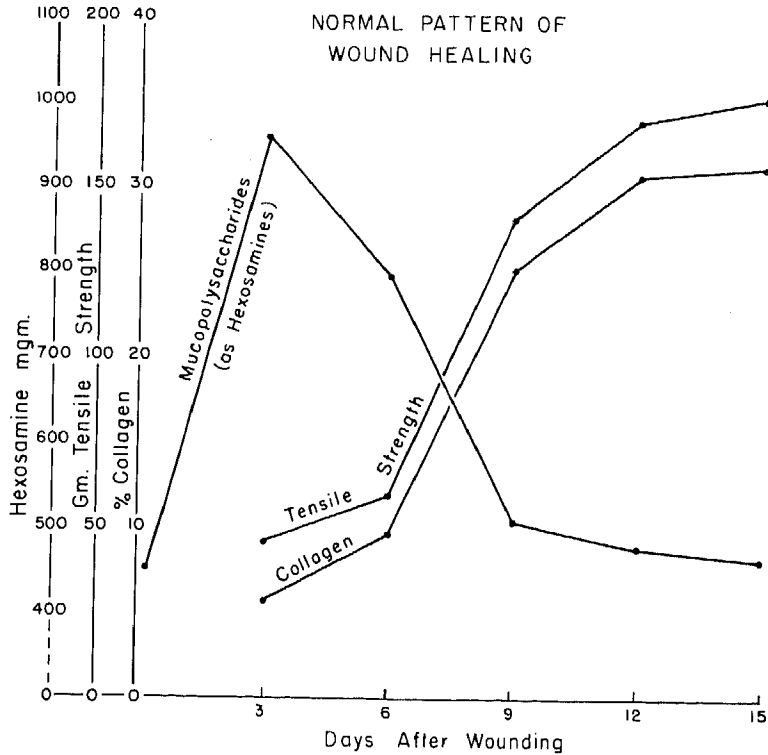


FIG. 1. The normal pattern of healing in the white rat. (Data from Dunphy and Udupa.²)

substances give to ground substance its gel-like, semi-sol nature and in an actual physical sense make it a "balsam" which may contribute to wound healing.

The exact origin of ground substance is not known, but there is considerable evidence to indicate that it is derived from the blood and from secretions of fibroblasts and mast cells. It is evident that ground substance, fibroblastic activity and collagen formation are closely interrelated. Since collagen is the principal constituent of a scar, it represents the end result of connective tissue repair in which ground substance presumably plays an essential role. The presence of collagen in a healing wound may be detected with some degree of exactness by staining technics and by chemical extraction for hydroxyproline, an amino acid found only in collagen. Although the various components of ground

substance cannot as yet be specifically identified by readily adaptable histochemical or chemical technics, certain procedures when taken together provide some indication of the state and presence of some of its components. Metachromasia, the phenomenon by which a basic blue dye stains tissue pink or red, occurs in embryonic connective tissue and in ground substance in certain stages of healing. It is probably related to the presence of an acid sulphated polysaccharide. Hale's colloidal iron stain, although less specific, may also indicate the presence of mucopolysaccharides. Quantitative measurement of mucopolysaccharides by chemical extraction for hexosamines also has definite limitations but certainly is indicative of a carbohydrate component in tissue. Finally, silver stains are quite specific for reticulin and reticular material. Here again, although the nature and

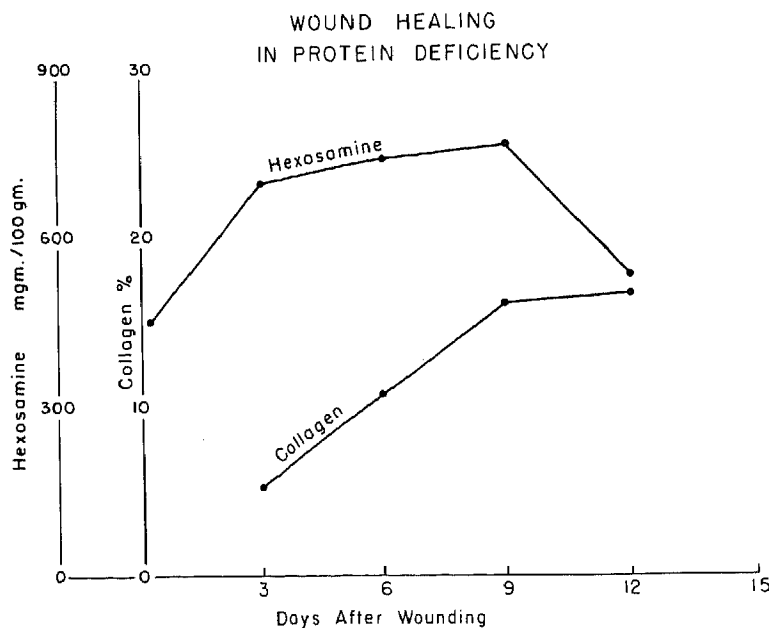


FIG. 2. The pattern of healing in protein depletion. (Data from Udupa, Woessner and Dunphy.²³)

role of reticulin is not certain, there are good grounds for considering it a stage in the development of collagen.^{10, 16}

We have attempted to elucidate the "humoral sequences" in repair by the following measurements:

1. For mucopolysaccharides: (a) Histochemical—Hale's colloidal iron stain,^{11, 20} metachromatic staining with toluidine blue, periodic acid Schiff stain.¹² (b) Chemical extraction—hydrolysis for hexosamine (Blix³).

2. For reticulin and reticular staining material—Silver impregnation.

3. For collagen: (a) Histochemical—Van Gieson's stain, Mallory's connective tissue stain. (b) Chemical extraction—hydrolysis for hydroxyproline (Neuman and Logan).¹⁷

OBSERVATIONS

The Normal Sequence of Repair: This has been described in detail in previous communications from which Figure 1 is reproduced.⁷ It can be seen that in the early stages of repair, from one to five days,

there appears to be a marked concentration of hexosamine in the wound. This impression receives confirmation from histochemical changes which are not depicted here but which show a distinct increase in metachromasia and colloidal iron staining during the period from two to six days after wounding. Silver stains show an appreciable amount of silver staining reticular material in the wound as early as the fifth and sixth days after injury. Since reticulin is a developmental stage of collagen, it appears a safe assumption that the soluble precursors of collagen are present in the wound by the fourth day or earlier.

The inverse relationship which exists between hexosamine concentration and collagen formation has led us to suggest that the early period of healing, far from being a "lag phase," should be regarded as a "productive" or "substrate" phase of repair. This is a period in which mucoproteins, sugars and the soluble protein precursors of collagen appear in the wound. From the sixth day onwards collagen formation pro-

ceeds. The curve of increase in concentration of collagen formation in the wound closely resembles that of increase in tensile strength. It is our impression that tensile strength is probably a function of collagen formation rather than merely of fibroblastic proliferation. The implications of these two phases of repair become more evident when one examines the sequences under conditions of protein and vitamin C deprivation.

The Pattern of Healing in Protein Depletion: The production of mucopolysaccharides and collagen in the wounds of protein depleted rats is distinctly altered as shown in Figure 2. The quantity per gram of tissue of these substances is less and the time required for its production is considerably lengthened. It is of interest that the single amino acid methionine if added to a non-protein diet has a remarkable effect in shifting the production of these materials qualitatively towards the normal. The details of these observations have been described elsewhere.²³

The Pattern of Healing in Ascorbic Acid Deficiency: The effect of ascorbic acid deficiency on the production of mucopolysaccharides and collagen in the healing wound has been studied in normal and scorbutic guinea pigs.

MATERIALS AND METHODS

Experiments were conducted on 72 male guinea pigs weighing between 250 and 350 Gm. Thirty-two animals were used as normal controls and 40 were placed on the standard scorbutogenic diet of Sherman²¹ for 20 days before wounding. The control animals were given a diet supplemented with vitamin C in the form of fresh vegetables and oranges.

Wounding was done as follows: Under ether anesthesia the back of the animal was shaved and the skin prepared with 2 per cent isopropyl alcohol. Two circular wounds were made on the interscapular area of the back of each animal measuring about 3 cm. in diameter. The skin, sub-

cutaneous tissue and superficial muscles of the back were excised. Bleeding points, if any, were clamped and ligated with fine catgut. No dressings were applied. The wounds were allowed to heal without any further local treatment.

On the fourth, eighth, twelfth and sixteenth days after wounding, animals were sacrificed by an overdosage of ether anesthesia. It should be noted that the day selected for taking samples in this series of animals differs from that previously recorded in normal and protein depleted animals. This was done because of the difficulty encountered in getting adequate samples of new tissue in three day wounds particularly in the scorbutic animals.

One of the two wounds in each animal was utilized for histologic and histochemical studies and the other for chemical analyses. Material for histologic study was fixed in Zenker's, 10 per cent formalin and 4 per cent freshly prepared lead acetate solution. It was then dehydrated, cleared and embedded in paraffin and cut at 6 μ . Stainings were done with haematoxylin and eosin, Van Gieson's collagen stain, Mallory's connective tissue stain and Gomori's silver impregnation stain. Histochemical stainings were done with periodic acid Schiff stain, metachromatic staining using 0.1 per cent toluidine blue and 30 per cent alcohol and Hale's colloidal iron stain as modified by Rinehart and Abul Haj.²⁰

For chemical determinations, samples of the granulation tissue and wound edges were taken, avoiding inclusion of obviously normal tissue. These were placed in acetone for one week, changing the solution three times during the period. A portion of these tissues were then utilized for the determinations of hexosamine and hydroxyproline by the methods of Blix¹⁸ and Neuman and Logan.¹⁷

Eight scorbutic animals were given a daily intramuscular injection of 25 mg. of ascorbic acid beginning on the eighth day after wounding. Four were sacrificed on

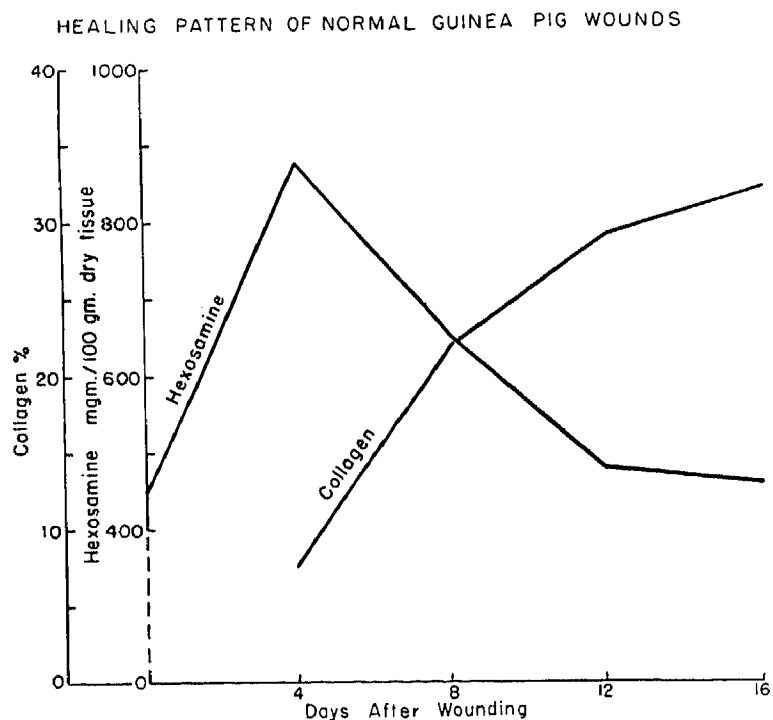


FIG. 3. The pattern of healing in the normal guinea pig (cf Table I).

the ninth day and four on the twelfth day to study the effect of ascorbic acid administration on hexosamine and hydroxyproline concentration in a scorbutic animal.

RESULTS

Normal Healing of Wounds in Guinea Pigs: The wounds of normal animals on the fourth day on histochemical examination revealed large numbers of immature fibroblasts invading the fibrin clot. There was well formed intercellular substance which stained metachromatically with toluidine blue. Positive stains were also obtained with P.A.S. and colloidal iron. The concentration of hexosamine and hydroxyproline in these tissues is depicted in Figure 3 and recorded in Tables I and II. It can be seen that on the fourth day there was a significant increase in the amounts of hexosamine in the wound in comparison with normal skin and subcutaneous tissue. There was also evidence of a small amount of collagen in the

wound on the fourth day. This may represent the inclusion of adjacent collagenous tissue in the sampling since histologically no collagen fibers can be seen at this time. It may also indicate the presence of small amounts of hydroxyproline and soluble precursors of collagen. This observation merits further study.

On the eighth day there were large numbers of newly formed collagen fibers around the fibroblasts. Chemical studies at this

TABLE I. *Hexosamine Content of Normal Wounds (Guinea Pigs)*

Normal Skin—450 mg./100 Gm. dry tissue (Persson)*

Post-operative Day	Mg. Hexosamine/100 Gm. Dry Tissue				Mean
4 day	845	866	868	930	877
8 day	637	611	659	705	653
12 day	476	444	483	507	478
16 day	473	460	455	506	474

*437 mg./100 Gm. dry tissue (Personal Data).




FIG. 4. Photomicrograph of a normal eight day wound (A) and an eight day scorbutic wound (B) stained by silver impregnation. Note the delicate reticulin fibrils in the normal wound in contrast to the globular appearing reticular material in the scorbutic wound. Quantitatively, however, there appears to be no deficiency of reticular staining material.

TABLE II. Collagen Content of Normal Wounds*
(Guinea Pigs)

Post-operative Day	Gm. Collagen/100 Gm. Dry Tissue		Mean
4 day	8.57	6.8	7.69
8 day	19.2	24.8	22.0
12 day	28.2	30.8	29.5
16 day	32.2		32.2

* We are indebted to Dr. J. Frederick Woessner of the Department of Biology, Massachusetts Institute of Technology for the hydroxyproline determinations.

time showed a rise in collagen content from 6 per cent to 20 per cent of dry weight. The hexosamine concentration of the intercellular substance has fallen below that found on the fourth day and there was correspondingly a diminution in the degree of metachromasia. The P.A.S. and colloidal iron stains were not as strongly positive as noted earlier. On the other hand, silver impregnation stains showed a considerable amount of reticular staining material throughout the wound (Fig. 4).

By the twelfth day the wounded area in the normal animal has filled with newly formed, young collagen fibers which can readily be demonstrated by Van Gieson's stain (Fig. 5). There are very few reticular

staining fibers in the area at this stage and stains for mucopolysaccharides show very little evidence of positive reaction. The contrast between a normal wound and a scorbutic twelve day wound when stained with Hale's colloidal iron technic is shown in Figure 6. By the sixteenth day the findings have changed comparatively little from the twelfth day except that histologically the collagen fibers appear denser and more mature. Chemical estimation for collagen, however, shows no significant increase in content over the twelve day wound.

The general pattern of healing in open, granulating wounds in the guinea pig conforms very closely to that previously described in the white rat.⁷

Healing in Scorbutus: In the scorbutic animals on the fourth day the wounds contain plenty of fibroblasts actively proliferating and invading the clots. The contrast histologically with the normal wound is not striking. There are also capillary endothelial cells found to be actively proliferating, but there seems less orientation of these cells towards capillary formation than is noted in the normal wound. The intercellular ground substance does not stain metachromatically, although the P.A.S. and colloidal iron stains are clearly positive in the scorbutic wound by the fourth day. The results




FIG. 5. Photomicrograph of a normal (A) and a scorbutic (B) twelve day wound stained for collagen with Van Gieson's stain. Note the immature cellular arrangement and lack of fibers in the scorbutic wound ($\times 720$).




FIG. 6. Photomicrograph of a normal (A) and a scorbutic (B) twelve day wound stained with Hale's colloidal iron technic. Note the mature cells, oriented fibers and pale, intercellular substance in the normal wound. The scorbutic wound shows a dense over-staining with the colloidal iron interpreted as indicative of a large amount of mucopolysaccharides in the immature ground substance.

of chemical analyses are shown in Figure 7 and recorded in Tables III and IV. The concentration of hexosamines is less than that seen in the normal wound. The same minimal amount of hydroxyproline was found in the scorbutic wound as in the normal wound and it is not clear whether this represents some hydroxyproline in collagen precursors or whether it is a result of sampling of collagenous tissue at the wound edges.

On the eighth day the fibroblasts are still actively proliferating and multiplying but appear somewhat less well oriented than in the normal wound. The cells appear large and immature and there is no evidence of

collagen fibers being laid down around them. When these tissues are stained with silver impregnation technic, however, one sees large collections of reticular material in the intercellular space. This material is thick and poorly oriented, occurring in globules rather than as fibrils (Fig. 4). The toluidine blue stain continues to show no metachromatic change although the P.A.S. and colloidal iron stain remains positive. The hexosamine content of the granulating wounds has risen moderately whereas in the normal animals it is clearly falling towards normal at this time. The most dramatic difference between the normal and scorbutic animals is seen in the collagen

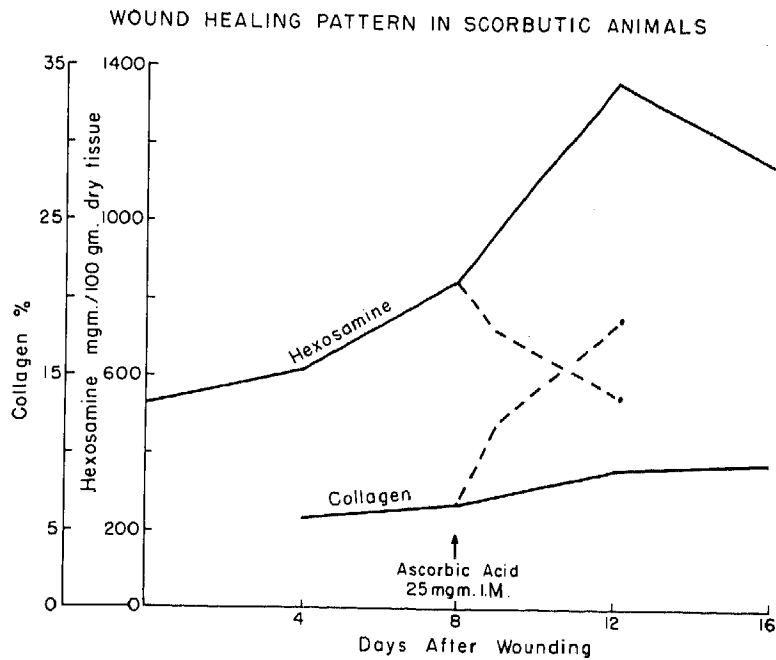


FIG. 7. The pattern of healing in scorbutic guinea pigs. The dotted lines indicate the alteration which follows the administration of 25 mg. of vitamin C daily intramuscularly (cf Tables III, IV and V).

content as measured by hydroxyproline concentration (Figs. 3 and 7).

By the twelfth day in the scorbutic wound the fibroblasts still show little evidence of maturing. Hale's colloidal iron and P.A.S. stain remain positive. The contrast between a normal twelve day wound and a twelve day scorbutic wound when stained with Hale's technic is depicted in Figure 6. The colloidal iron produces a deep, rich blue in the staining which appears dark in the black and white reproduction. It can be seen that in the scorbutic wound the en-

tire ground substance is heavily stained, whereas in the normal 12 day wound there are well formed collagen fibers, cellular activity has decreased and the ground substance stains quite faintly. The hexosamine content of the twelve day scorbutic wound remains high and very little collagen can be demonstrated by chemical extraction. This conforms with the histologic evidence of collagen lack. However, it is of great significance that as in the eight day wound silver stains show a large collection of reticular staining material. Since reticular

TABLE III. *Hexosamine Content of Scorbutic Wounds*
Skin of Scorbutic Animal—525 mg./100 Gm. Dry Tissue (Persson)*

Postoperative Day	Mg. Hexosamine/100 Gm. Dry Tissue							Mean
4 day	600	616	648	576	599	655	620	616
8 day	880	804	883	815	831	814	906	848
12 day	1330	1289	1371	1473	1576	1251	1278	1367
16 day	1188	1166	1341	1078	1004			1155

* 534 mg./100 Gm. Dry Tissue (Personal Data).

TABLE IV. *Collagen Content of Scorbutic Wounds*

Post-operative Day	Gm. Collagen/100 Gm. Dry Tissue					Mean
4 day	6.10	4.9	5.04	6.1	7.57	5.94
8 day	6.5	5.3	5.66	7.96	8.35	6.75
12 day	6.54	7.0	10.1	10.6	10.35	8.92
16 day		9.3				9.3

TABLE V. *Hexosamine and Collagen Content of Scorbutic Wounds after Treatment with Vitamin C*

Post-operative Day	Days of Treatment	Mg. Hexosamine/100 Gm. Dry Tissue		Mean
9 day	1 day	733	721	727
12 day	4 day	585	591	588
		Gm. Collagen/100 Gm. Dry Tissue		Mean
9 day	1 day	10.54	8.45	9.5
12 day	4 day	23.5	18.5	21.0

material is presumably a precursor of collagen, we interpret this finding as indicating a considerable quantity of protein precursors of collagen which are not properly oriented towards collagen formation.

The various findings in wounds on the sixteenth day were quite similar to those found on the twelfth day. Hexosamine content remains high. It is doubtful whether the differences in hexosamine concentration as depicted in Figure 7 between the twelfth and sixteenth days are of significance. It is evident, however, that the hexosamine concentration of these wounds has not fallen towards the normal levels seen in the control animals. By the sixteenth day the animals were quite ill and may have been suffering from multiple deficiencies. For this reason studies were not carried beyond the sixteenth day.

A most interesting observation was the rapidity with which alterations in hexosamine and hydroxyproline concentration followed the daily administration intramuscularly of 25 mg. of ascorbic acid to the scorbutic animals. This was started on the

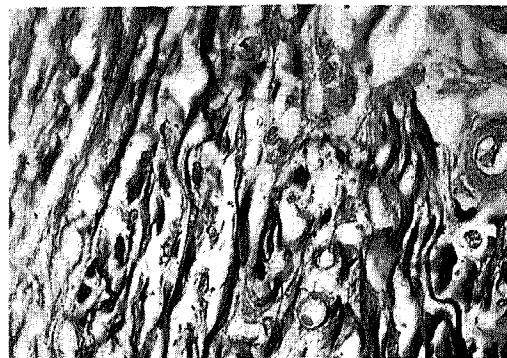


FIG. 8. Photomicrograph of a twelve day scorbutic wound after four days of treatment with intramuscular vitamin C. Note the cellular organization and collagen fibers (Van Gieson's stain $\times 720$). Contrast with Figure 5 (B).

eighth day in eight animals; four were sacrificed after 24 hours and the other four, four days later. The changes are depicted in the dotted line in Figure 7 and recorded in Table V. Histologic and histochemical observations confirm this finding (Fig. 8). Metachromasia could be demonstrated after 24 hours, and after four days there was distinctly less tissue which stained positively with Hale's colloidal iron and the P.A.S. stains.

Whatever the exact mechanism of ascorbic acid action, it accomplishes this with great rapidity and suggests to us that the basic materials for wound repair are present in the scorbutic wound, but an important key to collagen synthesis is lacking.

DISCUSSION

These observations provide a new perspective of wound healing. It is evident that distinct differences can be detected between normal repair on the one hand and repair in protein depleted and scorbutic animals on the other hand. It is very tempting to speculate upon the significance of these alterations and we have suggested that in protein deficiency there is a lack of the "building blocks" of repair, whereas in scorbutus the basic materials are present in adequate amounts but cannot be utilized until ascorbic acid is provided.

In protein depletion the addition of a single amino acid methionine restores the pattern of hexosamine and hydroxyproline concentration towards the normal.²³ The mechanism of this action is not clear, but presumably methionine permits more rapid utilization of the animal's body proteins. Williamson has shown that a direct relationship exists between gain in tensile strength and sulfur content of granulation tissue.²⁶ He has also shown that in the early stages of repair there is a high concentration of methionine, whereas in the later stages cysteine predominates.²⁷ The significance of these interrelationships are not entirely clear. Our own efforts to elucidate the mechanisms of action of methionine by giving S35 labeled methionine and sodium sulphate to normal and protein depleted animals 48 hours after wounding have not as yet furnished sufficient data on which to base conclusions. It is of interest, however, that when S35 sodium sulphate is given, there is much less concentration in the wound as shown by autoradiographs than when S35 labeled methionine is given. This contrast is particularly striking in the protein depleted animal. That this represents a specificity of action of methionine for the healing wound is evidenced in part by the fact that the S35 uptake of sodium sulphate and methionine appears to be essentially of the same order in samples of cartilage taken from the same animals. The entire subject of sulphur and sulphate metabolism in repair requires intensive study.

A comprehensive analysis of the enormous data, both experimental and clinical, which relates to the action of ascorbic acid in healing wounds is not within the scope of this paper. Comment will be restricted to the effect of ascorbic acid on ground substance. Wolbach at the conclusion of his classic study²⁸ on scorbutus felt that there was a lack of a specific substance which produced gelification of ground substance. He did not postulate a deficiency of ground substance. Similarly, Hunt's¹⁴ beau-

tiful histologic studies demonstrated no lack of fibroblastic proliferation or reticulin formation. He also showed that if normal guinea pigs with freshly healed wounds were placed on a scorbutogenic diet, newly formed collagen reverted to reticular-like precollagen. The histochemical studies of Gersch and Catchpole⁸ and Bradfield and Kodicek⁵ suggest that the state of mucopolysaccharides in the ground substance are abnormal, but that there is no lack of these materials. Further confirmation that there is no deficiency of mucopolysaccharides in scurvy comes from the work of Persson¹⁹ who showed that the tissue concentrations of hexosamine in scorbutic animals was increased. Penney and Balfour,¹⁸ however, because of the lack of metachromasia in ground substance in vitamin C deficiency concluded that there was a faulty production of mucopolysaccharides.

Our studies support the concept that there is no deficiency of mucopolysaccharides in ground substance. It may be that the state of polymerization of the acid polysaccharide is altered so as to prevent metachromasia. Walton and Ricketts²⁵ have shown that metachromasia is related to sulphation of acid polysaccharides and we²⁴ have shown elsewhere that the phenomenon of metachromasia in solutions of acid polysaccharide can be blocked by the addition of protein to the solution. A similar mechanism may prevent the phenomenon of metachromasia *in vivo*. Finally, the prompt appearance of collagen in the wound following the administration of vitamin C (Fig. 7) intramuscularly supports our concept that the "building blocks" of repair are at hand but a key to collagen synthesis is lacking.

In this same connection, however, the report of Kodicek and Loewi¹⁵ is of particular interest. While studying S35 sulphate uptake by granulation tissue they noted in normally healing wounds an inverse relationship between hexosamine and hydroxyproline concentration in maturing granulation tissue quite similar to that which we

have described. In comparing normal and scorbutic animals, however, they noted no significant difference in concentration of hexosamine in samples taken on the eighth and thirteenth days, whereas our data suggest an actual increase in hexosamine concentration. Their observations were made on wounds which had been closed primarily after excision of all the tendons in the hind leg. The method permitted sampling of pure granulation tissue in contrast to our technic in which small amounts of adjacent wounded tissue were included in the samples. Also, the animals in the studies of Kodicek and Loewi had been on a scorbutogenic diet for only ten days prior to wounding, whereas our animals had been on a scorbutic diet for 20 days. Whether these factors account for the difference in results or whether, as has occurred to us, there may be distinct differences in the mechanisms of repair in open wounds versus primarily closed wounds is a subject for further appraisal. Surface trauma and infection may influence the hexosamine concentration of open granulating wounds, particularly in depleted animals. Finally, it should not be concluded from these studies that the inverse relationship which has been demonstrated between hexosamine concentration and collagen formation necessarily indicates a causal relationship. Much more work in this area is needed.

The problems and questions raised in the preceding discussion have impelled us to search for a technic which would permit distinct and separate sampling of newly formed tissue and of the immediately adjacent wound tissue. The method described below we believe lends itself to this purpose and may provide a method for extending these observations to man.

THE SPONGE BIOPSY TECHNIC

The work of Grindlay²² and others has shown the feasibility of collecting material for study by implanting a polyvinyl alcohol sponge in various tissues. Struthers and

Grindlay²² have studied new bone formation and Boucek⁴ has employed it for analysis of tissue lipids.

We have encountered a number of technical difficulties in adapting this method to a study of wound healing. Reactions to the sponge are not always uniform and in the early stages of repair new tissue may be squeezed out of the sponge during excision. Preliminary data reveal that the rate of growth and chemical composition of the new tissue varies depending upon whether it is implanted in muscle or subcutaneous tissue. This suggests that the mechanism of repair in these tissues may have fundamental humoral differences requiring evaluation. Despite these and other difficulties we believe that with continued experience fairly uniform samples of new tissue can be obtained and the newly formed tissues can be clearly distinguished from the surrounding wound edges, yet uniform samples of the latter can also be taken for analysis.

A distinct advantage of this method is that one can quantify the amount of new tissue formed per unit weight of sponge implanted. This provides another dimension for the study of healing. There appear to be distinct differences in the amount of new tissue formed in normal and depleted animals. Another advantage of the sponge biopsy technic is that several samples can be taken from a single wound without sacrificing the animal or greatly disturbing the wound itself. This represents a distinct advance and makes the technical application of this method to the study of healing in man quite promising. Preliminary observations indicate that the sponge biopsy technic can be effectively applied to healing wounds in man.

SUMMARY

1. Chemical and histochemical studies provide a new perspective of wound healing based upon a "humoral" as well as a "cellular" approach.

2. Significant differences in the pattern

of healing in normal and depleted animals can be detected by these methods.

3. In ascorbic acid deficiency fibroplasia, mucopolysaccharide production and the formation of reticular procollagen material are not inhibited and may be considerably increased. The basic defect of repair in ascorbic acid deficiency appears to be one of collagen synthesis. Evidence is presented that this defect is corrected within twenty-four hours following the intramuscular administration of ascorbic acid.

4. A sponge biopsy technic which permits the study of repair by these methods in primarily closed wounds is described. Preliminary observations indicate that this can be applied effectively to a study of wound healing in man.

BIBLIOGRAPHY

1. Asboe-Hansen, G.: *Connective Tissue in Health and Disease*. Munksgaard, Copenhagen, 1954.
2. Bensley, S. H.: On the Presence, Properties and Distribution of the Intercellular Ground Substance of Loose Connective Tissue. *Anat. Rec.*, **60**: 93, 1934.
3. Blix, G.: The Determination of Hexosamines According to Elson and Morgan. *Acta Chem. Scandinav.*, **2**: 467, 1948.
4. Boucek, R. J. and N. L. Noble: Connective Tissue—A Technique for Its Isolation and Study. *Arch. Path.*, **59**: 553, 1955.
5. Bradfield, J. R. G. and E. Kodicek: Abnormal Mucopolysaccharide and 'Precollagen' in Vitamin C-Deficient Skin Wounds. *Proc. Biochem. Soc.*, **49**: 17, 1951.
6. Clark, E. R. and E. L. Clark: Further Observations on Living Lymphatic Vessels in the Transparent Chamber in the Rabbit's Ear—Their Relation to the Tissue Spaces. *Am. J. Anat.*, **52**: 273, 1933.
7. Dunphy, J. E. and K. N. Udupa: Chemical and Histochemical Sequences in the Normal Healing of Wounds. *N. E. J. M.*, **253**: 847, 1955.
8. Gersh, I. and H. R. Catchpole: The Organization of Ground Substance and Basement Membrane and Its Significance in Tissue Injury, Disease and Growth. *Am. J. Anat.*, **85**: 457, 1949.
9. Grindlay, J. H. and J. M. Waugh: Plastic Sponge Which Acts as a Framework for Living Tissue: Experimental Studies and Preliminary Report of Use to Reinforce Abdominal Aneurysms. *A. M. A. Arch. Surg.*, **62**: 288, 1951.
10. Gross, J.: A Study of the Aging of Collagenous Connective Tissue of Rat Skin with the Electron Microscope. *Am. J. Path.*, **26**: 708, 1950.
11. Hale, C. W.: Histochemical Demonstration of Acid Polysaccharides in Animal Tissues. *Nature (London)*, **157**: 802, 1946.
12. Hotchkiss, R. D.: Microchemical Reaction Resulting in Staining of Polysaccharide Structures in Fixed Tissue Preparations. *Arch. Biochem.*, **16**: 131, 1948.
13. Howes, E. L., J. W. Sooy and S. C. Harvey: The Healing of Wounds as Determined by Their Tensile Strength. *J. A. M. A.*, **92**: 42, 1929.
14. Hunt, A. H.: The Role of Vitamin C in Wound Healing. *Brit. J. Surg.*, **28**: 436, 1940.
15. Kodicek, E. and G. Loewi: The Uptake of (35S) Sulphate by Mucopolysaccharides of Granulation Tissue. *Proc. Royal Soc.*, **144B**: 100, 1955.
16. Mallory, F. B. and F. Parker, Jr.: Reticulin. *Am. J. Path.*, **3**: 515, 1927.
17. Neuman, R. E. and M. A. Logan: Determination of Collagen and Elastin in Tissues. *J. Biol. Chem.*, **186**: 549, 1950.
18. Penney, J. R. and B. M. Balfour: The Effect of Vitamin C on Mucopolysaccharide Production in Wound Healing. *J. Path. & Bact.*, **61**: 171, 1949.
19. Persson, B. H.: Studies on the Connective Tissue Ground Substance; Histochemical Features of Ground Substance Mucopolysaccharides; Organization of Ground Substance in Ascorbic Acid Deficiency and Its Modification by Action of Cortisone. *Acta Soc. Med. Upsalien. (Suppl. 2)*, **58**: 3, 1953.
20. Rinehart, J. F. and S. K. Abul-Haj: Improved Method for Histochemical Demonstration of Acid Mucopolysaccharides in Tissues. *Arch. Path.*, **52**: 189, 1951.
21. Sherman, H. C., V. K. LaMer and H. L. Campbell: The Quantitative Determination of the Antiscorbutic Vitamin (Vitamin C). *J. Am. Chem. Soc.*, **44**: 165, 1922.
22. Struthers, A. M., J. H. Grandlay and F. A. Figi: An Experimental Study of Formation of Autogenous Bone Within Polyvinyl Sponge. *Proc. Mayo Clinic*, **30**: 462, 1955.
23. Udupa, K. N., J. F. Woessner and J. E. Dunphy: The Effect of Methionine on the Production of Mucopolysaccharides and Col-

- lagen in Healing Wounds of Protein-Depleted Animals. *Surg. Obst. Gyn.*, 102: 639, 1956.
24. Udupa, K. N. and J. E. Dunphy: The Effect of Ascorbic Acid on Metachromasia in Solutions of Protein and Acid Polysaccharide. *J. Histochem. & Cytochem.* (To be published)
25. Walton, K. W. and C. R. Ricketts: Investigation of the Histochemical Basis of Metachromasia. *Brit. J. Exp. Path.*, 35: 227, 1954.
26. Williamson, M. B. and H. J. Fromm: Utilization of Sulfur Amino Acid During Healing of Experimental Wounds. *Proc. Soc. Exp. Biol. and Med.*, 83: 329, 1953.
27. Williamson, M. B. and H. J. Fromm: Incorporation of Sulfur Amino Acids into the Proteins of Regenerating Wound Tissue. *J. Biol. Chem.*, 212: 705, 1955.
28. Wolbach, B. S. and P. R. Howe: Intercellular Substances in Experimental Scorbutus. *Arch. Path. and Lab. Med.*, 1: 1, 1926.

DISCUSSION.—DR. ORVAR SWENSON, Boston, Massachusetts: I wish to commend Dr. Dunphy for opening up a new field of investigation. Some years ago we investigated the composition of fracture hematoma, and it is through Dr. Dunphy's work that our interest in this field has been renewed. We have been able to demonstrate that in the first four days of wound healing there is a spectacular rise in mucoprotein. The problem is sampling. Dr. Dunphy's idea of using a sponge is indeed an ingenious one.

DR. JOHN A. SCHILLING, Rochester, New York: I, too, would like to commend Dr. Dunphy for this work, which, along with the work of Dr. Howes, is very fundamental and emphasizes that the so-called lag phase is a period of intense biologic activity. Perhaps it is in this period that all of us as surgeons can learn factors that will help us to push this curve to the left as we look at it from a clinical point of view.

We have used a somewhat different method for a number of years to secure wound fluid, namely, the implantation of a wire mesh cylinder, which is obliterated by granulation tissue, enabling a cellular study as well as analysis of fluid. The most recent study^o really raises more questions than it answers, but it was related to the ultracentrifugal analysis of this fluid and to the Tiselius patterns.

There is a marked difference in the low density lipoprotein levels in wound fluid secured this way. First, in wound fluid the low density lipoproteins are low, yet they are high in the serum of a wounded animal. At the same time, if you look at the Tiselius pattern, the alpha and beta globulins are significantly elevated, and may be included in this category. In other words, some chemical changes occur. Thirdly, the gamma globulin is elevated in wound fluid; fibrinogen is absent.

The significance of this is a matter of conjecture, but the study of wound fluid and the fluid phase, as emphasized by Dr. Dunphy, seems certainly a fundamental contribution. Again, I would like to congratulate him on his study.

^o *Proc. Soc. Exp. Biol. & Med.* 89: 189-192, 1955.

DR. AMOS R. KOONTZ, Baltimore, Maryland: Every surgeon certainly ought to be interested in wound healing. Whether he is or not, this paper by Dr. Dunphy is most stimulating. I would like to ask him one question about the role of fibrin in wound healing.

In about 1903, I believe, Hertzler showed that in intestinal anastomosis, when fibrin collects in the trough between the loops of the anastomosed bowel, it intensely facilitated wound healing. Baitsel, at Yale, in around 1916 demonstrated in tissue culture the advantage of fibrin in wound healing. He believed that fibrin was actually converted into connective tissue fibers.

I would like to know exactly how fibrin plays a part. I never have exactly understood it. Does it increase the growth of fibroblasts by furnishing more protein, or just how does it work? Thank you very much.

DR. DAVID ROBINSON, Kansas City, Kansas: This very interesting and fascinating study which Dr. Dunphy has just reported is of importance because it gets to the fundamentals of wound healing, or at least it tends to add basic knowledge.

One of the difficulties we have had when studying wound healing has been a lack of adequate tools other than just observation. Could one grow cells in tissue culture and measure them quantitatively, one might be able to get a quantitative assay of some meaning. Unfortunately there are too many imponderables and difficulties in tissue culture to make a good quantitative cell count unless one might employ the hela cell as a tool for the study of stimulator or inhibitor substances.

We have been especially interested, first, in stimulator substances, and have come to no very basic conclusions in tissue cultures studies. Of late we have been interested in inhibitor substances, particularly the role of the mast cell in wound healing, hoping that we might identify the mucopolysaccharide that is present in the wound as the inhibitor substance. There is some evidence to believe that the mucopolysaccharide released from mast cells may be an inhibitor; it may be heparin; it may be histamine; it may be some other substances which to date cannot be identified. One of

the difficulties of histochemical assays is that we cannot be quite sure what the chemical substance is that combines with the dye which is being studied.

I appreciate and have enjoyed this presentation by Dr. Dunphy and his associates. It is a real contribution to our knowledge today.

DR. J. ENGLEBERT DUNPHY, Boston, Massachusetts: I don't think I can answer Dr. Koontz's

question. Fibrin may contribute to the first stage in the formation of collagen as part of certain soluble protein precursors. What is in it, I really don't know, but I suspect that when it is added to tissue culture or to a wound it is providing some of these precursors of collagen. Beyond that, I cannot go. It is one of the things we are interested in.

I would like to thank the discussants very much for their remarks.