

## THE EFFECT OF CHRONIC HYPOVITAMINOSIS C ON THE METABOLISM OF CHOLESTEROL AND ATHEROGENESIS IN GUINEA PIGS

E. GINTER, J. BABALA AND J. ČERVENĚ

*Institute of Human Nutrition Research, Bratislava (Czechoslovakia)*

(Received June 2nd, 1969)

---

### SUMMARY

Guinea pigs with varying intakes of ascorbic acid (0.5, 5 and 50 mg per 24 h) were receiving an atherogenic diet with addition of 0.3 % cholesterol during 140 days. In guinea pigs with a chronic deficiency of vitamin C (0.5 mg for 24 h) a significantly higher accumulation of cholesterol in liver, adrenal glands and small intestine was observed in comparison with the group receiving 50 mg of vitamin C for 24 h. Concentrations of cholesterol in the same organs of the group receiving 5 mg of vitamin C per 24 h were within these extreme data. A significantly negative correlation was confirmed to exist between cholesterol concentration in liver, adrenal glands and small intestine and saturation of tissues with vitamin C; with decreasing saturation of tissues with vitamin C, the accumulation of cholesterol in the relevant tissue was increasing. Cholesterol levels in brain and blood serum were not significantly influenced by differing intake of vitamin C. The most advanced atheromatous changes were found in aorta and coronary arteries of the hypovitaminous group (0.5 mg of vitamin C per 24 h). High doses of vitamin C (50 mg per 24 h) did not prevent the appearance of morphological changes in vascular system but only slowed down the process of atheromatous reconstruction.

---

Key words: *Atherogenesis – Atherogenic diet – Guinea pig – Hypovitaminosis C – Tissue cholesterol*

---

### INTRODUCTION

Data on the effect of vitamin C deficiency on cholesterol metabolism and vascular system are very contradictory. According to WILLIS<sup>1</sup>, within a short period of time scorbutic guinea pigs show atheromatous changes in aorta without being fed

an atherogenic diet. GORE *et al.*<sup>2,3</sup> did not observe changes of this type in aorta of scorbutic guinea pigs. Similarly, much contradictory data is found in the literature describing metabolic disturbances in acutely scorbutic guinea pigs, *e.g.* opinions differ as to the effect of acute avitaminosis C on the level of serum cholesterol<sup>4-9</sup>. All data obtained in experiments with acutely scorbutic guinea pigs could be strongly influenced by secondary nonspecific effects, *e.g.* refusal of food accompanied by rapid decrease in body weight, loss of blood due to hemorrhages, etc.

In order to avoid all these difficulties, we have used a model of chronic vitamin C deficiency<sup>10</sup> in which small doses of ascorbic acid prevent an appearance of an acute deficiency but will not prevent a sudden drop in levels of ascorbic acid in tissues. When using this model, we have found that, in guinea pigs with a chronic deficiency of vitamin C, a significant accumulation of cholesterol in liver occurs<sup>11</sup>. When guinea pigs were fed an atherogenic diet supplemented with cholesterol, the effect of ascorbic acid deficiency was seen on increased accumulation of cholesterol in a number of other tissues, including the aorta wall<sup>12</sup>. The effect of ascorbic acid deficiency on morphology of vascular system was not significant in this experiment, possibly a result of a relatively short period of administering an atherogenic diet. The present communication deals with results attained by studying the effect of a long-term vitamin C hyposaturation on biochemical and morphological changes in guinea pigs fed an atherogenic diet.

#### MATERIALS AND METHODS

Male guinea pigs, initially weighing 400–500 g, were used for the experiment. They were fed a modified Lunde's scorbutogenic diet<sup>16</sup> *ad libitum*. The atherogenic diet used was of the same composition, the only exception being an addition of 0.3 % cholesterol after dissolution in butter, a normal component of the diet<sup>17</sup>.

Guinea pigs were divided into 4 groups:

- (1) Control group on a scorbutogenic diet without cholesterol supplement with 5 mg of vitamin C per 24 h.
- (2) Hypovitaminous group on an atherogenic diet supplemented with 0.5 mg of vitamin C per 24 h.
- (3) A group on an atherogenic diet supplemented with 5 mg of vitamin C per 24 h.
- (4) A group on an atherogenic diet supplemented with 50 mg of vitamin C per 24 h.

Various doses of vitamin C in a 20 % sucrose solution were administered by peroral probe to guinea pigs three times weekly. The experiment took 139–142 days to complete, and finally the guinea pigs were decapitated after an 18-h deprivation of food. Following weighing of the internal organs, concentration of total cholesterol in blood serum and various tissues was determined according to Liebermann<sup>13</sup>, after extraction according to FOLCH *et al.*<sup>14</sup>. Concentration of vitamin C was determined in liver, spleen and adrenal glands<sup>15</sup>. Histological investigation of myocardium,

TABLE 1  
BODY WEIGHT INCREMENTS AND WEIGHTS OF ORGANS IN CONTROL AND CHOLESTEROL-FED GUINEA PIGS GIVEN VARIOUS DOSES OF ASCORBIC ACID

Parameter	Control group	Cholesterol-fed groups			Statistical significance control group against
		0.5 mg of vitamin C	5 mg of vitamin C	50 mg of vitamin C	
		0.5	5	50	
Body weight increment (g)	193 ± 62 <sup>a</sup> (6) <sup>b</sup>	60 ± 34 (12)	141 ± 36 (14)	180 ± 38 (9)	—
Spleen (mg)	1008 ± 83 (6)	1157 ± 101 (12)	1582 ± 98 (14)	1948 ± 303 (9)	0.01
Adrenals (mg)	412 ± 50 (6)	281 ± 15 (12)	289 ± 14 (14)	345 ± 22 (9)	0.01
Liver (g)	19.3 ± 2.2 (6)	46.4 ± 3.3 (12)	56.1 ± 3.1 (14)	58.3 ± 3.6 (9)	0.001

<sup>a</sup> Standard error of the mean.

<sup>b</sup> Number of animals.

TABLE 2  
 VITAMIN C LEVELS (MG PER 100 g WET TISSUE) IN THE TISSUES OF CONTROL AND CHOLESTEROL-FED GUINEA PIGS GIVEN VARIOUS DOSES OF ASCORBIC ACID

Tissue	Control group	Cholesterol-fed groups			Statistical significance control group against		
		0.5 mg of vitamin C	5 mg of vitamin C	50 mg of vitamin C			
		0.5	5	50			
Liver	3.70 ± 0.30 (6)	0.78 ± 0.10 (12)	2.55 ± 0.16 (14)	3.60 ± 0.23 (9)	0.001	0.002	—
Spleen	11.07 ± 1.25 (6)	3.26 ± 0.36 (12)	7.75 ± 0.52 (14)	11.58 ± 0.82 (9)	0.001	0.01	—
Adrenals	19.80 ± 1.48 (6)	5.98 ± 1.10 (12)	22.90 ± 1.65 (14)	33.39 ± 6.09 (7)	0.001	—	—

TABLE 3

TOTAL CHOLESTEROL CONCENTRATION (MG PER 100 g WET TISSUE) IN THE TISSUES OF CONTROL AND CHOLESTEROL-FED GUINEA PIGS GIVEN VARIOUS DOSES OF ASCORBIC ACID

Tissue	Control group	Cholesterol-fed groups			Statistical significance				
		0.5 mg of vitamin C	5 mg of vitamin C	50 mg of vitamin C	control group against 0.5	5	50	50 mg vitamin C group against	5
Liver	638 ± 113 (6)	6622 ± 548 (12)	5611 ± 416 (13)	3509 ± 350 (9)	0.001	0.001	0.001	0.001	0.002
Adrenals	3061 ± 287 (6)	7942 ± 890 (11)	7782 ± 671 (13)	5186 ± 840 (9)	0.002	0.001	—	0.05	0.05
Small intestine	221 ± 31 (6)	364 ± 23 (12)	317 ± 17 (14)	282 ± 20 (9)	0.01	0.01	—	0.02	—
Brain	971 ± 94 (6)	1284 ± 51 (12)	1237 ± 77 (13)	1311 ± 102 (9)	0.01	—	0.05	—	—
Blood serum	198 ± 29 (6)	239 ± 17 (11)	237 ± 15 (14)	263 ± 17 (9)	—	—	—	—	—

thoracic aorta and liver was made in all animals. The staining used was hematoxylin-eosin, Mallory's PTAH, PAS, Halle, Sudan IV and Okamoto's reaction for cholesterol.

The results were statistically evaluated by Student's *t* test, and correlations were determined by the method of least squares on the Olivetti Programma 101 computer.

## RESULTS

Table 1 lists weight increases and weights of organs of guinea pigs from the control group and from the groups receiving the atherogenic diet. Addition of cholesterol to the diet resulted in a decrease in weight increases, especially evident in the group with a chronic deficiency of vitamin C. On the other hand, the group receiving high doses of ascorbic acid (50 mg per 24 h) and the controls showed practically the same weight increases. Under the effect of cholesterol diet, the weights of liver and spleen were significantly increased. The smaller increase in the weight of these organs, observed in the group with chronic deficiency of vitamin C, can be explained by slower rate of growth of the animals in this group. On the contrary, the weight of adrenal glands in groups receiving cholesterol was significantly lower than in control animals, with the exception of guinea pigs receiving high doses of vitamin C.

Table 2 lists levels of vitamin C in tissues of guinea pigs of all experimental groups. As expected, the levels of vitamin C in organs of hypovitaminous guinea pigs were very low, approximately on the level of animals with an acute avitaminosis C<sup>11</sup>. Guinea pigs fed the cholesterol diet with a dose of 5 mg of vitamin C per 24 h had a significantly lower concentration of vitamin C in liver and spleen in comparison with a control group receiving equal doses of ascorbic acid. It is noteworthy that in guinea pigs fed an atherogenic diet even very high doses of ascorbic acid (50 mg per 24 h) did not result in an increased accumulation of vitamin C, which would significantly surpass the level of vitamin C in control animals receiving a tenfold lower dose of ascorbic acid and a diet without addition of cholesterol.

Table 3 lists cholesterol concentration in the four organs and blood serum of guinea pigs of all experimental groups. In the hypovitaminous group, the administration of cholesterol diet caused a highly significant increase in the cholesterol level in all four organs under investigation. On the other hand, in the group receiving 50 mg of vitamin C per 24 h, a significant increase in the cholesterol level was observed only in liver. In brain this increase was at the limit of statistical significance, and in the remaining two organs an increased accumulation of cholesterol was not statistically confirmed. Comparison of cholesterol levels in guinea pig tissues receiving 0.5 or 50 mg of ascorbic acid per 24 h shows that in small intestine, adrenal glands and especially in liver of the hypovitaminous group, a higher amount of cholesterol was deposited. The cholesterol levels in the group receiving 5 mg of vitamin C per 24 h are situated between those two extreme levels.

In guinea pigs of all groups fed a cholesterol diet, a correlation was made between the cholesterol level with vitamin C concentration in liver, adrenal glands and small

intestine; in the case of the small intestine, the concentration of cholesterol was correlated with the concentration of vitamin C in spleen, since no analysis of vitamin C level in small intestine was performed. Results indicated that in all three organs there existed a statistically significant negative correlation between the level of cholesterol and vitamin C. The correlation coefficient for liver was  $r = -0.4758$ ,  $P < 0.01$ ; for adrenals  $r = -0.3653$ ,  $P < 0.05$ ; and for small intestine  $r = -0.5047$ ,  $P < 0.01$ . This correlation does not apply to brain and blood serum, since the levels of cholesterol are not dependent on a vitamin C dose in these two cases.

Histological investigation revealed that there are no evident morphological changes in the control group without cholesterol supplement. The group receiving a diet with addition of cholesterol and 5 mg of vitamin C per 24 h displayed edematous inhibition of vascular wall in the aorta and swelling of the elastic fibers. Proliferation of endothelium and some foam cells were observed in the intima. In myocardium there was a slight mononuclear and histiocytic perivascular cellulization around the atheromatously changed branches of coronary arteries. Atheromatous masses were transparent, mural or obliterating, giving a positive reaction with Sudan IV and acquiring greenish color by Okamoto's treatment for cholesterol. Some groups of perivascular myocardial cells were acidophilic with pycnotic nuclei. In liver, diffuse steatosis, proliferation of Kupffer's cells, monocellular necroses and moderate fibroplasia in portal and periportal spaces was observed.

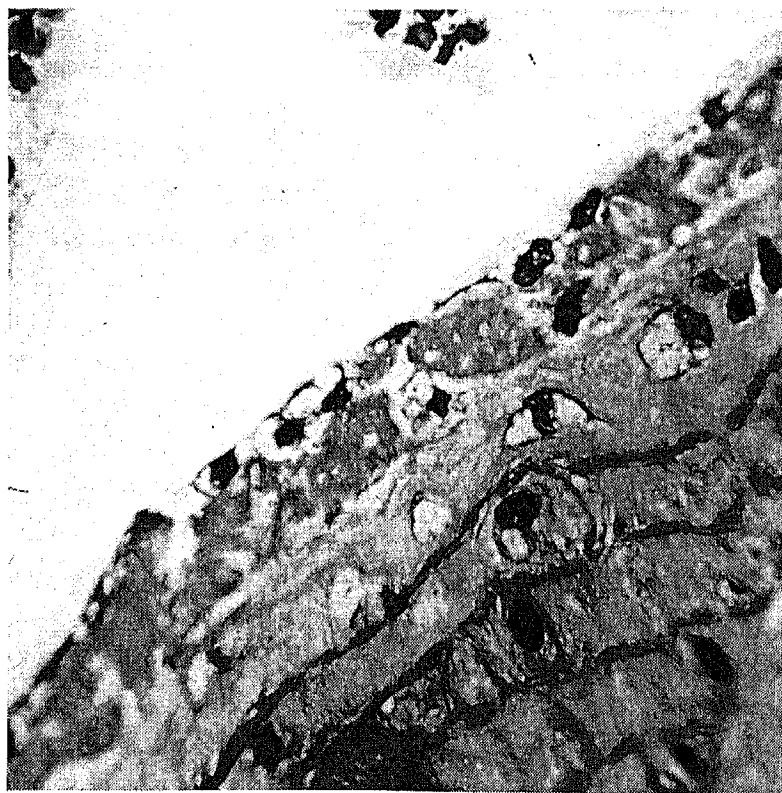


Fig. 1. Homogeneous or finely granular and vacuolized coagulated layer on the intima covered with endothelial cells, occurrence of lipophagic elements and edema of aortic wall with swelling and splitting of elastic fibers. Hypovitaminous guinea pig, fed cholesterol diet. H-E, 600  $\times$ .

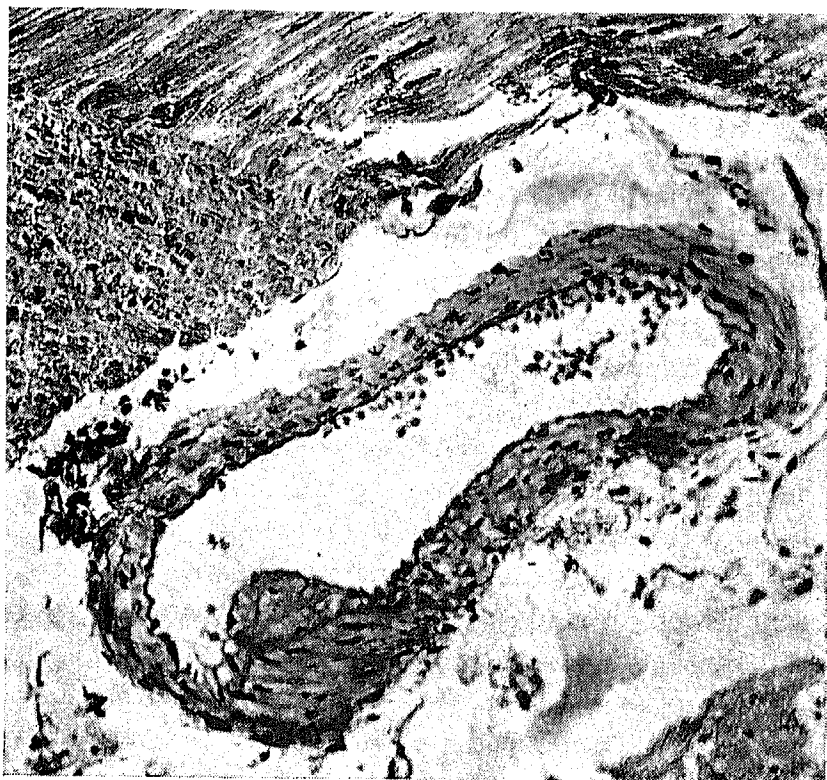

Fig. 2. Parietal coagulated mass protruding into the lumen of coronary artery with incipient endothelization in a hypovitaminous guinea pig, fed cholesterol diet. H-E, 200  $\times$ .

Hypovitaminous group, receiving the diet with cholesterol displayed similar changes in the aorta, apart from the presence of partially homogeneous or finely granular and vacuolized layer on the intima, covered with some endothelial cells and pervaded by lipophages. This layer gave no positive reaction for fibrin. In edematous aortic wall, swelling and splitting of elastic fibers was observed (Fig. 1). In myocardium, there were incipient formations (Figs. 2 and 3) and advanced atheromas of coronary arteries and their branches with scanty perivascular cellulization or hemorrhages and regressive changes of adjacent myocardial cells. Under the endocardium, minute foci of granulation tissue and perivascular small cicatrices were observed. In the liver, apart from diffuse steatosis, monocellular necrosis, hyperplasia of Kupffer's cells and bile ducts were present. Some foci of granulation tissue with occurrence of some lipid clefts and multinuclear crystalphages were also found in hepatic parenchyma (Fig. 4). Proliferation of the connective tissue was more extensive.

In the aorta of the group receiving the cholesterol diet and high doses of vitamin C (50 mg per 24 h), in comparison with the hypovitaminous group, there were some changes of smaller extent. Accumulation of lipidic substances and presence of foam cells in the intima were rare. In myocardial vessels, similar atheromatous changes were observed. Atheromatous substances in branches of coronary arteries were either obliterating or mural, overlapped by endothelial cells. Focal subendocardial mono-

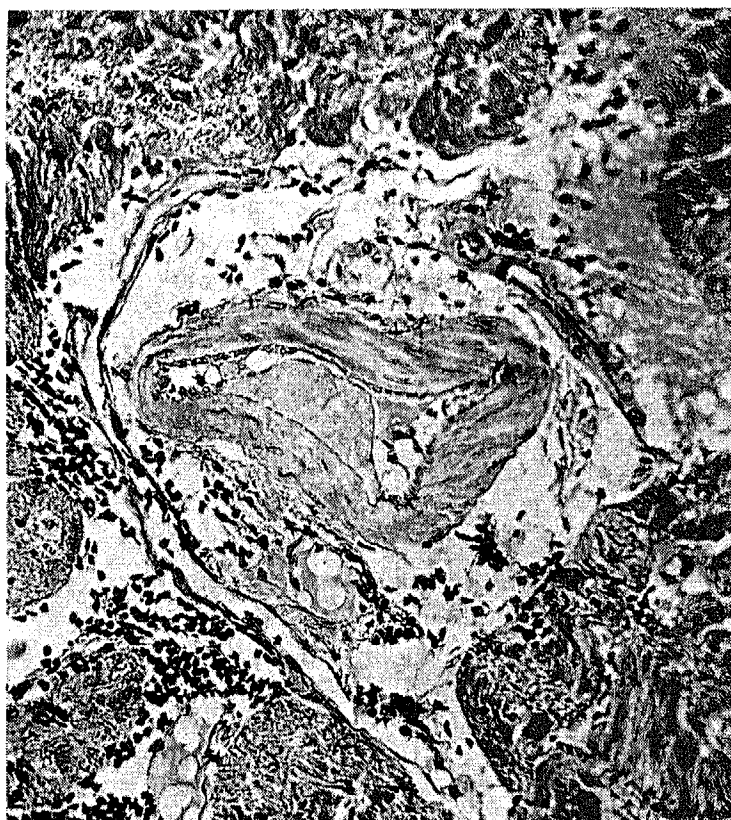


Fig. 3. Endothelized atheromatous substance, beneath loss of endothelium and beside proliferated endothelial cells in a coronary branch of hypovitaminous guinea pig, fed cholesterol diet. H-E, 200  $\times$ .

nuclear and histiocytary infiltrations as the regressive changes of myocardial cells, *i.e.* monocellular coagulation necroses, were not often present. Proliferation of connective tissue and a more pronounced hyperplasia of bile ducts in steatotic liver were observed. Necrobiotic changes and small foci of granulation tissue with crystallophages were also found.

A complete evaluation of the histological findings suggests, that there are no expressive qualitative histo-morphological differences between different experimental groups. However the hypovitaminous group, in comparison with the group on high doses of vitamin C, showed somewhat more numerous and marked changes in the aorta. Differences between a hypovitaminous group and the group receiving 5 mg of vitamin C per 24 h were only less significant. Initial changes in aorta, coronary arteries and its branches appear identical. Edema and focal damage to the endothelial cells were followed by deposition of homogeneous or finely granular and vacuolized masses upon the intima (Figs. 1-3). These masses having the characteristic of coagulated lipemic plasma and disintegrated thrombocytes or some erythrocytes are succesively endothelized and form the basis of further atheromas penetrated by lipophages or cholesterol clefts. In this experiment too, as in our previous study<sup>18</sup>, thrombogenic origin of these vascular lesions is assumed.

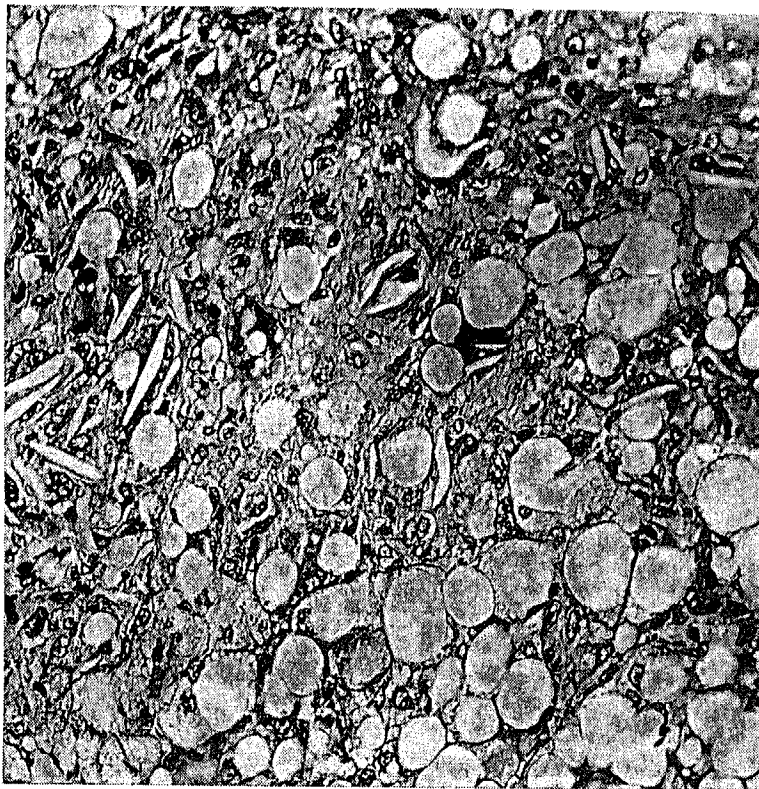


Fig. 4. Granulation tissue with lipid clefts in steatotic liver of hypovitaminous guinea pig, fed cholesterol diet. H-E, 200  $\times$ .

#### DISCUSSION

The results may be unambiguously interpreted in the sense that chronic vitamin C deficiency in guinea pigs is associated with increased cholesterol accumulation in their organism. Between the saturation of the organism with vitamin C and the cholesterol concentration in various tissues, there exists a significant indirect correlation. The cholesterol concentration in a number of tissues is significantly higher in vitamin-C-deficient guinea pigs in comparison with animals saturated with high doses of ascorbic acid.

Small biochemical and morphological differences between a hypovitaminous group and the group receiving 5 mg of ascorbic acid per 24 h are not surprising, since the tissues of animals of this group were only insufficiently saturated with vitamin C, too. It seems that the dose of 5 mg of vitamin C *pro die*, fully sufficient for guinea pigs fed standard diets, does not sufficiently cover the vitamin C consumption when cholesterol is added in the diet. A dose of 50 mg of ascorbic acid per 24 h showed an evident protective effect against accumulation of exogenous cholesterol into tissues and to a certain degree also against an occurrence of conspicuous pathomorphological changes in vascular system. However, the saturation of tissues with vitamin C was also in this group not extraordinarily high. This can be explained by an increased consumption of vitamin C due to cholesterol diet<sup>16</sup> and also by relatively low absorption of perorally administered ascorbic acid in guinea pigs<sup>19</sup>. An intraperitoneal

administration of similar doses of ascorbic acid can increase the level of vitamin C in guinea pig liver as much as ten times<sup>20</sup>. It is not impossible to suggest that in these conditions the protective effect of ascorbic acid would be more pronounced.

The fact that pathomorphological finding on vascular system of hypovitaminous guinea pigs seems to be the most conspicuous cannot be explained by a different level of cholesterol circulating in blood. In agreement with our previous study<sup>12</sup>, the varying doses of vitamin C did not significantly effect the cholesterol levels in serum. SOKOLOFF *et al.*<sup>21,22</sup> found that high doses of ascorbic acid prevented a decrease in lipoprotein lipase in blood serum of rabbits and rats fed a cholesterol diet. We may anticipate that this factor played its role also in our experiments. Any future research will have to question whether an increased sensitivity of vascular system of hypovitaminous guinea pigs is not connected with the effect of long-term deficiency of vitamin C on metabolism of vascular wall. WILLIS AND FISHMAN<sup>23</sup> reported on localized depletion of ascorbic acid in segments of human arteries showing an increased sensitivity to atherosclerosis. In the segments of arteries where the ascorbic acid content is increased, the occurrence of atheromas is less frequent.

The mechanism of the increased accumulation of cholesterol in the tissues of vitamin-C-deficient guinea pigs has not been elucidated up to now. Preliminary results of our experiments with [4-<sup>14</sup>C]cholesterol indicate that this phenomenon depends on a disturbed catabolism of cholesterol to bile acids. It is known that ascorbic acid has an important function in hydroxylation of cyclic structures in a whole range of substances, *e.g.* proline<sup>24</sup>, aromatic amino acids<sup>25</sup> and tryptophan<sup>26</sup>. Analogically, it is possible to anticipate the involvement of ascorbic acid in hydroxylation of cholesterol, *i.e.* in the initial stage of transformation of this substance to bile acids.

#### REFERENCES

- 1 WILLIS, G. C., The reversibility of atherosclerosis, *Canad. med. Ass. J.*, 1957, 77: 106.
- 2 GORE, I., T. FUJINAMI AND T. SHIRAHAMA, Endothelial changes produced by ascorbic acid deficiency in guinea pigs, *Arch. Path.*, 1965, 80: 371.
- 3 GORE, I., Y. TANAKA, T. FUJINAMI AND M. L. GOODMAN, Aortic acid mucopolysaccharides and collagen in scorbutic guinea pigs, *J. Nutr.*, 1965, 87: 311.
- 4 MOURIQUAND, G. AND A. LEULIER, Sur la teneur en cholestérine de quelques organes des Cobayes soumis au régime scorbutogène, *C. R. Soc. Biol. (Paris)*, 1925, 93: 1314.
- 5 BOLKER, H. I., S. FISHMAN, R. D. H. HEARD, V. J. O'DONNELL, J. L. WEBB AND G. C. WILLIS, The incorporation of acetate-1-<sup>14</sup>C into cholesterol and fatty acids by surviving tissues of normal and scorbutic guinea pigs, *J. exp. Med.*, 1956, 103: 199.
- 6 BANERJEE, S. AND H. D. SINGH, Cholesterol metabolism in scorbutic guinea pigs, *J. biol. Chem.*, 1958, 233: 336.
- 7 BANERJEE, S. AND P. K. GHOSH, Metabolism of acetate in scorbutic guinea pigs, *Amer. J. Physiol.*, 1960, 199: 1064.
- 8 BANERJEE, S. AND A. BANDYOPADHYAY, Plasma lipids in scurvy: Effect of ascorbic acid supplement and insulin treatment, *Proc. Soc. exp. Biol. (N.Y.)*, 1963, 112: 372.
- 9 GINTER, E., L. BILISICS AND J. ČERVEŇ, Cholesterol metabolism under conditions of acute and chronic vitamin C deficiency in guinea pigs, *Physiol. bohemoslov.*, 1965, 14: 466.
- 10 GINTER, E., P. BOBEK AND M. OVEČKA, Model of chronic hypovitaminosis C in guinea pigs, *Int. J. Vitamin Res.*, 1968, 38: 104.
- 11 GINTER, E., P. BOBEK, Z. KOPEC, M. OVEČKA AND K. ČEREY, Metabolic disorders in guinea pigs with chronic vitamin C hyposaturation, *Z. Versuchstierk.*, 1967, 9: 228.
- 12 GINTER, E., P. BOBEK, J. BABALA AND E. BARBIERIKOVÁ, The effect of ascorbic acid on the lipid metabolism of guinea pigs fed an atherogenic diet, *Cov Vasa*, 1969, 11: 65.

- 13 RICHTERICH, R., *Klinische Chemie. Theorie und Praxis*, Karger, Basle, New York, 1965.
- 14 FOLCH, J., M. LEES AND G. H. SLOANE-STANLEY, A simple method for the isolation and purification of total lipids from animal tissues, *J. biol. Chem.*, 1957, 226: 497.
- 15 ROE, J. H. AND C. A. KUETHER, Determination of ascorbic acid in whole blood and urine through the 2:4-dinitrophenylhydrazine derivate of dehydroascorbic acid, *J. biol. Chem.*, 1943, 147: 339.
- 16 GINTER, E., The effect of diet cholesterol on vitamin C metabolism of various laboratory animals, *Acta med. Acad. Sci. hung.*, 1969, In press.
- 17 GINTER, E., J. BABALA, P. BOBEK AND Z. DUMBALOVÁ, Model of experimental hypercholesterolemia and atherosclerosis in the guinea pig, *Cor Vasa*, 1968, 10: 126.
- 18 BABALA, J. AND E. GINTER, Coronary changes experimentally produced in guinea pigs by hypercholesterolemia, *Nutr. Dieta*, 1968, 10: 133.
- 19 PENNEY, J. R. AND S. S. ZILVA, The fixation and retention of ascorbic acid by the guinea pig, *Biochem. J.*, 1946, 40: 695.
- 20 REID, M. E., Ascorbic acid metabolism in guinea pigs in relation to growth, *J. Nutr.*, 1950, 42: 347.
- 21 SOKOLOFF, B., M. HORI, C. C. SAELHOF, T. WRZOLEK AND T. IMAI, Aging, atherosclerosis and ascorbic acid metabolism, *J. Amer. geriat. Soc.*, 1966, 14: 1239.
- 22 SOKOLOFF, B., M. HORI, C. SAELHOF, B. McCONNELL AND T. IMAI, Effect of ascorbic acid on certain blood fat metabolism factors in animals and man, *J. Nutr.*, 1967, 91: 107.
- 23 WILLIS, G. C. AND S. FISHMAN, Ascorbic acid content of human arterial tissue, *Canad. med. Ass. J.*, 1955, 72: 500.
- 24 ROBERTSON, W. VAN B., The biochemical role of ascorbic acid in connective tissue, *Ann. N. Y. Acad. Sci.*, 1961, 92: 159.
- 25 LA DU, B. N. AND V. G. ZANNONI, The role of ascorbic acid in tyrosine metabolism, *Ann. N. Y. Acad. Sci.*, 1961, 92: 175.
- 26 COOPER J. R., The role of ascorbic acid in the oxidation of tryptophan to 5-hydroxytryptophan, *Ann. N. Y. Acad. Sci.*, 1961, 92: 208.